

DOI: 10.4274/mjima.2017.17

Mediterr J Infect Microb Antimicrob 2017;6:17

Erişim: <http://dx.doi.org/10.4274/mjima.2017.17>

# Acute Cervical Myelitis as a Rare Complication of Pneumococcal Meningitis in Adults

## Erişkinde Pnömomokokal Menenjitin Nadir Bir Komplikasyonu Akut Servikal Miyelit

Fatih TEMOÇİN<sup>1</sup>, Hatice KÖSE<sup>1</sup>, Serap TEMOÇİN<sup>2</sup>, Halil ÖNDER<sup>3</sup>

<sup>1</sup>Yozgat City Hospital, Clinic of Infectious Diseases and Clinical Microbiology, Yozgat, Turkey

<sup>2</sup>Yozgat City Hospital, Clinic of Radiology, Yozgat, Turkey

<sup>3</sup>Yozgat City Hospital, Clinic of Neurology, Yozgat, Turkey

**Keywords:** Cervical myelitis, pneumococcal meningitis, *Streptococcus pneumoniae*, magnetic resonance imaging, vancomycin

**Anahtar Kelimeler:** Servikal miyelit, pnömokokal menenjit, *Streptococcus pneumoniae*, manyetik rezonans görüntüleme, vankomisin

Dear Editor,

Meningitis can be defined as an inflammatory disease of the protective membranes covering the central nervous system. Early diagnosis and treatment is critical as it can potentially lead to permanent damage in the brain as well as spinal cord<sup>[1]</sup>. Such that, despite current advances in the intensive care and antibiotic therapies, the morbidity and mortality rates are quite high. Various neurological complications have been reported to accompany meningitis, however, spinal cord involvement is an extremely rare phenomenon<sup>[2]</sup>.

This paper illustrates a case of pneumococcal meningitis complicated with acute cervical spinal cord myelitis in an immunocompetent adult patient.

A 52-year-old female patient with an unremarkable medical history was admitted to our hospital with sudden onset headache and confusion in March 2017. Physical examination revealed otitis media and purulent discharge from the left ear. Vital signs recorded were as follows; temperature: 37.8 °C, blood pressure: 110/80 mmHg, heart rate: 122 bpm, and respiratory rate: 18/min. On neurological examination, the patient was evaluated as disorientated and noncooperative and nuchal rigidity (both Kernig's sign and Brudzinski's sign) was positive. The patient had a Glasgow Coma Scale (GCS) score of 11 (E: 4, M: 5, V: 2). Other neurological examinations

were within the normal ranges; no pyramidal sign was present.

Taken together the clinical and laboratory findings, a preliminary diagnosis of meningitis was established. Hence, lumbar puncture (spinal tap) was performed, in which microscopic examination of the cerebrospinal fluid (CSF) showed 360 leukocytes/mm<sup>3</sup> (95% polymorphonuclear) and 60 erythrocytes/mm<sup>3</sup>. There were no findings on Gram and methylene stain of the CSF. Biochemical examination of the CSF revealed a glucose level of 6 mg/dL (concurrent blood glucose level: 195 mg/dL) and a total protein concentration of 150 mg/dL (normal range: 15–45 mg/dL). The patient was admitted to the intensive care unit for further examinations and close follow-up. The blood and CSF samples were cultured. Ceftriaxone 2x2 g (4 g/day) and ampicillin 4x3 g (200 mg/kg/day) therapies were started promptly. Craniocervical magnetic resonance imaging (MRI) was normal (Figure 1a). On the second day, a moderate resolution of headache and neck stiffness was achieved and her consciousness level has significantly improved up to GCS of 14. On the other hand, fever still persisted on the third day evaluation. However, on the third day of follow-up, swallowing difficulty, lisping and right hemiparesis developed in a rapidly progressive course (in a one-day period). Concurrently, neurological examination showed dysarthria and diminished bilateral gag reflex. The movement of the right eye towards the right side was disturbed consistent with

Cite this article as: Temoçin F, Köse H, Temoçin S, Önder H. Acute Cervical Myelitis as a Rare Complication of Pneumococcal Meningitis in Adults. *Mediterr J Infect Microb Antimicrob*. 2017;6:17.



Address for Correspondence/Yazışma Adresi: Fatih Temoçin MD,

Yozgat City Hospital, Clinic of Infectious Diseases and Clinical Microbiology, Yozgat, Turkey

Phone: +90 505 841 03 48 E-mail: [ftemucin@yahoo.com.tr](mailto:ftemucin@yahoo.com.tr) ORCID ID: [orcid.org/0000-0002-4819-8242](http://orcid.org/0000-0002-4819-8242)

Received/Geliş Tarihi: 13.03.2017 Accepted/Kabul Tarihi: 18.07.2017

©Copyright 2017 by the Infectious Diseases and Clinical Microbiology Specialty Society of Turkey  
Mediterranean Journal of Infection, Microbes and Antimicrobials published by Galenos Yayınevi.

6<sup>th</sup> nerve paralysis. There was an apparent weakness in tongue movements compatible with bilateral 12<sup>th</sup> nerve palsy. Motor examination showed right-sided paralysis (upper extremity: 2/5, lower extremity: 3-/5). Deep tendon reflexes were normoactive in the upper extremities but significantly increased in the lower extremities. Babinski's sign was bilaterally positive, suggestive of first motor neuron dysfunction. The sensorial assessment showed right-sided hypoesthesia in the upper and lower extremities. Contrast-enhanced craniocervical MRI showed a longitudinal, edematous, contrast-enhanced lesion in the cervical cord (Figure 1b). Conventional brain MRI sequences revealed normal brain parenchyma, however, contrast enhancement of the cranial nerves (which were probably influenced considering the neurological examination findings of cranial nerve abnormalities) could not be evaluated due to the low quality of the contrast-enhanced sequences (Figure 2). Based on the clinical course which had developed soon after meningitis (not an interval period was present) and neuroimaging findings, infectious cervical myelitis developing due to meningitis was considered in the forefront.

Blood culture results were positive for penicillin-resistant *S. pneumoniae* serotype 19f (resulted on the 3<sup>rd</sup> day of admission). Antimicrobial susceptibility of *S. pneumoniae* was determined by E-test in accordance with the criteria of the Clinical and Laboratory Standards Institute<sup>[3]</sup> and serotyping was made with the Quellung reaction. The multiplex polymerase chain reaction (PCR) (BioFire FilmArray® Biomerieux, USA) analysis of the CSF was positive for *S. pneumoniae* while viral pathogens (Herpes simplex virus type 1-2, Enterovirus and Varicella-Zoster virus) (The LightCycler® Roche, Switzerland) were negative. Hence, ampicillin was replaced with vancomycin 4x500 mg (2 g/day). During follow-up, the myelitis clinical findings gradually

recovered. Such that, neurological examination on the 2<sup>nd</sup> week revealed complete recovery of cranial nerve disturbances. Motor and sensory examinations were completely normal. Only left sided Babinski's sign was shown to be positive. Remarkably, spinal MRI, which was performed three weeks after admission, showed totally resolution of myelitis (Figure 1c).

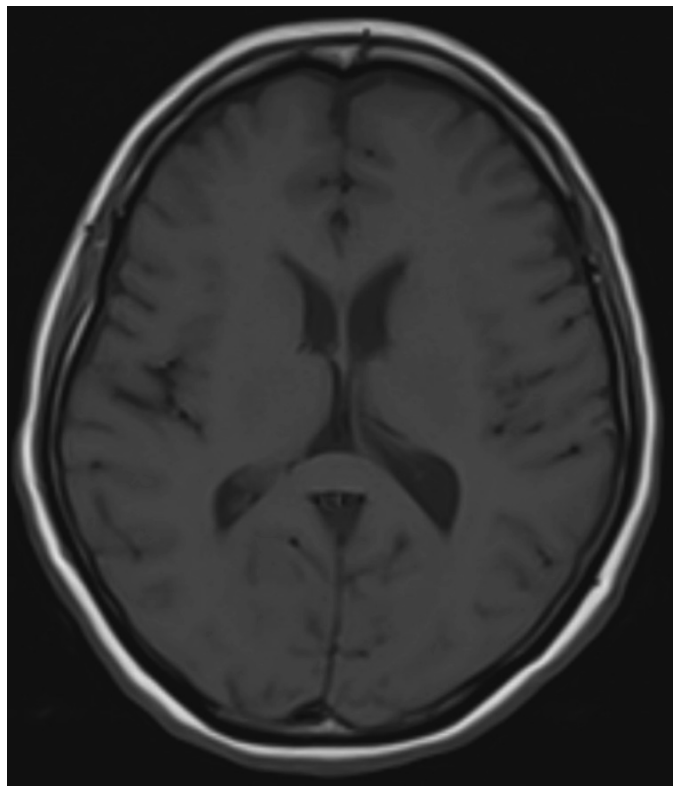


Figure 2. Conventional brain magnetic resonance imaging sequence

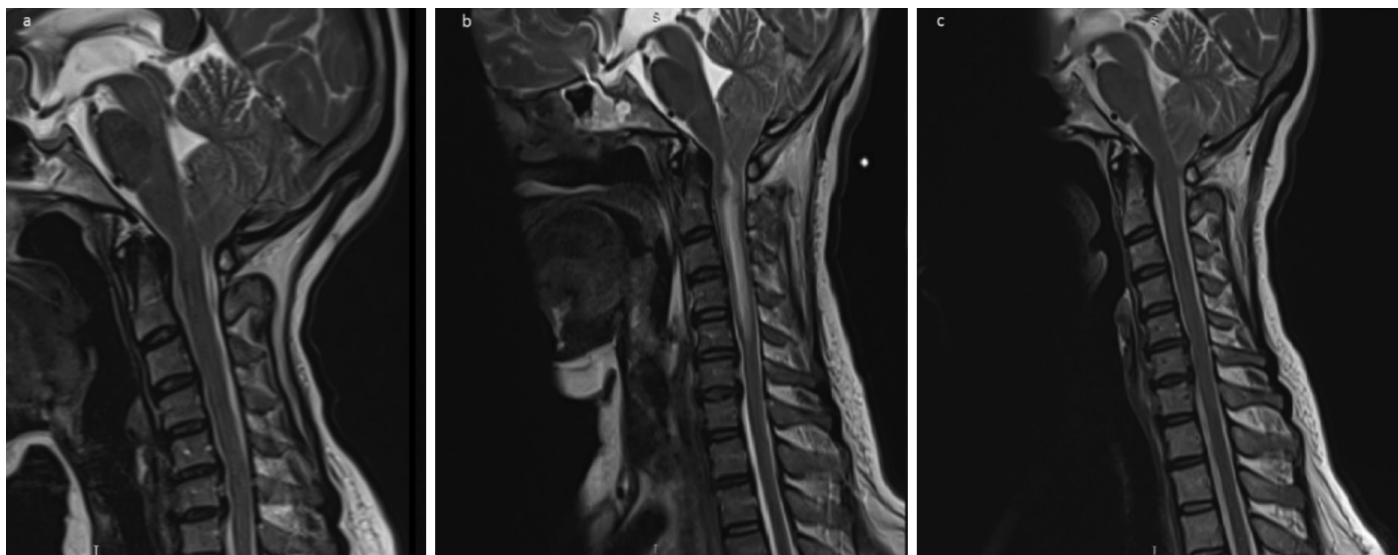


Figure 1. Enhanced craniocervical magnetic resonance imaging images. a) The magnetic resonance imaging (MRI) image of the patient recorded at the time of the first admission. b) The MRI image recorded on the third day of follow-up. Myelitis at the level of cervical cord (C2-C6). c) The MRI image recorded after three weeks of treatment

Infectious myelitis is a very rare complication of pneumococcal meningitis and most of the cases reported in the literature include pediatric patients<sup>[4-6]</sup>. Clinical picture and neuroimaging findings have been reported extremely rarely in adult population<sup>[7,8]</sup>. Hence, we assume that the clinical and neuroimaging findings of our patient which were developed as a devastating complication of pneumococcal meningitis, may give a valuable contribution in this regard. In addition, dramatic recovery of the clinical as well as neuroimaging findings also gives critical points emphasizing the importance of early diagnosis and prompt administration of appropriate antibiotherapy.

Cranio-cervical MRI revealed extensive intramedullary, edematous myelitis at the cervical cord extending from C2 to C6 level. First, acute demyelinating diseases were taken into consideration, but these diagnoses were withdrawn due to clinical inconsistency and neuroimaging findings rather leading to a consideration of infectious myelitis (massive and edematous lesion).

We think that the clinical course of the disease and MRI imaging were mainly consistent with cervical cord myelitis which was considered as a complication of pneumococcal meningitis. However, we also think that as biopsy investigation of the spinal cord was absent in our patient, a possibility of autoimmune myelitis occurring due to meningitis infection cannot be totally excluded. On the other hand, inconsistent with this possibility, only antibiotherapy had provided a total recovery of the patient supporting the view of infectious etiology for myelitis.

In the literature, majority of bacterial meningitis cases complicated with myelitis have been reported to recover with a sequelae clinic<sup>[4]</sup>. The subject in our study recovered without clinically remarkable sequelae after one month of the treatment. Early initiation of treatment and subsequent modification based on microorganism growth are very important in the case of bacterial meningitis. Regimens including vancomycin are recommended for empirical treatment in the regions with a higher rate of penicillin or cephalosporin resistance<sup>[9]</sup>. In our case also, early initiation of treatment and appropriate modifications of adding vancomycin after the detection of penicillin resistance had probably influenced this positive clinical outcome.

In the case of bacterial meningitis, administration of dexamethasone either before starting the antibiotherapy or concurrently with the first antibiotic dose is strongly recommended<sup>[9]</sup>. However, we did not prescribe steroids, since antibiotic treatment had been started before the patient was referred to our clinic. While there are reports of positive effects of steroid treatment, particularly on hearing loss and neurological deficit<sup>[10]</sup>, its effect on the development of spinal myelitis is not known in meningitis. Although the clinical course of this index

case may give crucial perspectives in this regard, the rationale of steroid treatment in cases of meningitis complicated with myelitis is warranted to be investigated in future reports of case series.

Another topic of discussion may be related with the importance of pneumococcal vaccination as infections can lead to devastating complications as in our case. In community-acquired meningitis, *S. pneumoniae* is the most frequently isolated pathogen<sup>[2]</sup>. In our case also, the presence of *S. pneumoniae* serotype 19f was observed in blood culture and this microorganism was also demonstrated in the CSF by PCR. Our patient had no previous history of pneumococcal vaccination. Currently used conjugated pneumococcal vaccines contain *S. pneumoniae* serotype 19f, which was isolated from this subject. There should be more emphasis on the importance of vaccination for protection against invasive pneumococcal infections. Pneumococcal vaccine was recommended for the patient to prevent recurrent meningitis.

In conclusion, the possibility of spinal cord involvement should also be kept in mind in the case of acute bacterial meningitis. In the case of symptoms of paraplegia and quadriplegia, the whole spinal cord should be scanned with MRI. Moreover, via the presentation of our case, we re-emphasize the importance of vaccination in the prevention of invasive pneumococcal meningitis and related complications.

## Ethics

**Peer-review:** Externally and internally peer-reviewed.

**Informed Consent:** Written informed consent was obtained from the patient who was reported in this paper.

## Authorship Contributions

Surgical and Medical Practices: F.T., H.K., S.T., H.Ö., Concept: F.T., H.K., S.T., H.Ö., Design: F.T., H.K., S.T., H.Ö., Data Collection or Processing: F.T., H.K., S.T., H.Ö., Analysis or Interpretation: F.T., H.K., S.T., H.Ö., Literature Search: F.T., H.K., S.T., H.Ö., Writing: F.T., H.K., S.T., H.Ö.

**Conflict of Interest:** No conflict of interest was declared by the authors.

**Financial Disclosure:** The authors declared that this study received no financial support.

## References

1. Raymond F, Boucher N, Allary R, Robitaille L, Lefebvre B, Tremblay C, Corbeil J, Gervais A. Serotyping of *Streptococcus pneumoniae* based on capsular genes polymorphisms. *PLoS one*. 2013;8:e76197.
2. Kastenbauer S, Pfister HW. Pneumococcal meningitis in adults: spectrum of complications and prognostic factors in a series of 87 cases. *Brain*. 2003;126:1015-25.

3. CLSI: Performance Standards for Antimicrobial Susceptibility Testing; Twenty-Fifth Informational Supplement; Document M100-S85. CLSI. 2007;27:40-1.
4. Moffett KS, Berkowitz FE. Quadriplegia complicating *Escherichia coli* meningitis in a newborn infant: Case report and review of 22 cases of spinal cord dysfunction in patients with acute bacterial meningitis. Clin Infect Dis. 1997;25:211-4.
5. Kikuchi M, Nagao K, Muraosa Y, Ohnuma S, Hoshino H. Cauda equina syndrome complicating pneumococcal meningitis. Pediatr Neurol. 1999;20:152-4.
6. Puvabanditsin S, Wojdylo EW, Garrow E, Kalavantavanich K. Group B streptococcal meningitis: A case of transverse myelitis with spinal cord and posterior fossa cysts. Pediatr Radiol. 1997;27:317-8.
7. Kastenbauer S, Winkler F, Fesl G, Schiel X, Ostermann H, Yousry TA, Pfister HW. Acute severe spinal cord dysfunction in bacterial meningitis in adults: MRI findings suggest extensive myelitis. Arch Neurol. 2001;58:806-10.
8. Višković K, Mustapić M, Kutleut M, Lepur D. Acute Pneumococcal Myelitis in an Adult Patient. J Glob Infect Dis. 2014;6:73-5.
9. Tunkel AR, Hartman BJ, Kaplan SL, Kaufman BA, Roos KL, Scheld WM, Whitley RJ. Practice guidelines for the management of bacterial meningitis. Clin Infect Dis. 2004;39:1267-84.
10. Brouwer MC, McIntyre P, de Gans J, Prasad K, van de Beek D. Corticosteroids for acute bacterial meningitis. Cochrane Database Syst Rev. 2010:CD004405.