

# Is *Papillotrema (Cryptococcus) laurentii* an Emerging Concern? A Literature Review and Case Series from a Tertiary Hospital

## *Papillotrema (Cryptococcus) laurentii* Giderek Artan Bir Sorun mu Oluyor? Üçüncü Basamak Bir Hastanede Olgu Serisi Eşliğinde Literatür Derlemesi

© Müge Toygar Deniz<sup>1\*</sup>, © Sonay Arslan<sup>2</sup>

<sup>1</sup>Kocaeli University Faculty of Medicine, Department of Infectious Diseases and Clinical Microbiology, Kocaeli, Türkiye

<sup>2</sup>Muş Bulanık State Hospital, Clinic of Infectious Diseases and Clinical Microbiology, Muş, Türkiye

### Abstract

**Introduction:** Cryptococcosis is a significant opportunistic fungal infection, particularly affecting immunocompromised individuals. *Papillotrema laurentii* has been increasingly reported in recent years, especially in immunosuppressed patients. This study aims to provide guidance on the diagnosis and treatment of *P. laurentii*-related infections or colonization, along with a review of the existing literature.

**Materials and Methods:** Patients with *P. laurentii* isolated in any culture sample between 2017 and 2022 were included in this study. A literature search was conducted using the electronic databases Scopus, Web of Science, MEDLINE (PubMed), and Google Scholar.

**Results:** Over the past 5 years, *P. laurentii* was identified in culture samples from nine patients in our hospital. A literature review revealed 35 publications reporting a total of 40 cases of *P. laurentii* infection between 1998 and 2022. The most common risk factors included the use of broad-spectrum antibiotics and the presence of invasive devices or catheters.

**Conclusion:** Although *P. laurentii* is considered a rare pathogen, it can cause infections of various organ systems. Therefore, clinicians should be aware that this uncommon fungal species may act as an infectious agent, particularly in patients receiving broad-spectrum antibiotics or steroid therapy.

**Keywords:** *Papillotrema laurentii*, fungal diseases, Cryptococcosis

### Öz

**Giriş:** Kriptokokozis, özellikle immün sistemi baskılanmış hastalarda görülen önemli bir fırsatçı mantar enfeksiyonudur. *Papillotrema laurentii* son yıllarda özellikle immün sistemi baskılanmış hastalarda bildirilmiştir. Bu makalede literatür derlemesi yapılarak *Papillotrema laurentii* ile ilişkili enfeksiyonların veya kolonizasyonların tanı ve tedavisine rehberlik etmek amaçlanmıştır.

**Gereç ve Yöntem:** Çalışmamıza, 2017-2022 yılları arasında herhangi bir kültür örneğinde *Papillotrema laurentii* izolasyonu saptanan hastalar dahil edilmiştir. Literatür taramaları, Scopus, Web of Science, MEDLINE (PubMed) ve Google Scholar gibi elektronik veri tabanlarında gerçekleştirilmiştir.

**Bulgular:** Son beş yıl içerisinde hastanemizde kültür örneklerinde *Papillotrema laurentii* izole edilen dokuz hasta tespit edilmiştir. Yapılan literatür taramasında, 1998-2022 yılları arasında *Papillotrema laurentii* enfeksiyonu gelişen toplam kırk olguyu içeren otuz beş yayın bulunmuştur. Geniş spektrumlu antibiyotik kullanımı ile invaziv araç veya kateter varlığı en sık karşılaşılan risk faktörleri olarak belirlenmiştir.

**Sonuç:** Nadir bir etken olarak bildirilen *Papillotrema laurentii*, birçok sistemi tutarak çeşitli enfeksiyonlara yol açabilmektedir. Bu nedenle, özellikle geniş spektrumlu antibiyotik ve steroid tedavisi kullanan hastalarda, bu tür nadir etkenlerin enfeksiyon etkeni olarak karşımıza çıkabileceği akılda tutulmalıdır.

**Anahtar Kelimeler:** *Papillotrema laurentii*, mantar hastalıkları, Kriptokokkoz

**Cite this article as:** Toygar Deniz M, Arslan S. Is *Papillotrema (Cryptococcus) laurentii* an emerging concern? A literature review and case series from a tertiary hospital. *Mediterr J Infect Microb Antimicrob* 2025;14:24316.8.



Address for Correspondence/Yazışma Adresi: Müge Toygar Deniz, MD. Kocaeli University Faculty of Medicine, Department of Infectious Diseases and Clinical Microbiology, Kocaeli, Türkiye  
E-mail: [mugedeniz90@gmail.com](mailto:mugedeniz90@gmail.com) ORCID ID: [orcid.org/0000-0002-6946-2727](https://orcid.org/0000-0002-6946-2727)  
Received/Geliş Tarihi: 07.10.2024 Accepted/Kabul Tarihi: 04.03.2025

Epub: 13.05.2025

Published: xxxxxxxxxx



©Copyright 2025 The Author. Published by Galenos Publishing House on behalf of Infectious Diseases and Clinical Microbiology Specialty Society of Turkey. Licensed under a Creative Commons Attribution-NonCommercial-NoDerivatives 4.0 International License (CC BY-NC-ND 4.0)

## Introduction

*Papillotrema laurentii*, formerly known as *Cryptococcus laurentii*, is an encapsulated basidiomycetous yeast. Cryptococcosis is a major opportunistic fungal infection, primarily affecting immunocompromised patients<sup>[1]</sup>. However, in approximately 30% of cases, no identifiable predisposing factors are present<sup>[2]</sup>. The most common pathogenic species associated with Cryptococcosis are *C. neoformans* and *C. gattii*. Notably, around 80% of reported cases of non-*neoformans* or non-*gattii* Cryptococcosis have been attributed to *C. laurentii* and *C. albidus*<sup>[3]</sup>.

Although *P. laurentii* is generally considered a saprophytic and rare yeast, reports of invasive infections have increased in recent years<sup>[4,5]</sup>. Documented infections caused by *P. laurentii* include involvement of the lungs, central nervous system, bloodstream, urinary tract, and musculoskeletal system<sup>[6]</sup>. While this species is typically regarded as non-pathogenic to humans, such infections have been reported.

This study aims to investigate *P. laurentii* infections or colonization detected in our hospital and review the existing literature to emphasize the clinical relevance of *C. laurentii*-related infections and provide guidance for their diagnosis and treatment.

## Materials and Methods

Patients with *P. laurentii* isolated from any culture sample between 2017 and 2022 were included in this study. Demographic and clinical data were obtained from the hospital database. Infection was defined as the proliferation of the microorganism in the host leading to disease symptoms due to invasion, whereas colonization was characterized by the presence of the microorganism without causing a disease response. Sputum samples were assessed using the Bartlett classification. According to this method, active inflammation was defined by the presence of 10-25 or more leukocytes at 10x magnification and fewer than 10 epithelial cells in the same field. A literature search was conducted using the electronic databases Scopus, Web of Science, MEDLINE (PubMed), and Google Scholar. Among the identified studies, 3 were retrospective cohort studies, 7 were systematic reviews, and 31 were case reports. No restrictions were placed on language or publication date. Both pediatric and adult populations were included, and reference lists of the retrieved studies were manually reviewed. This study followed the Preferred Reporting Items for Systematic Reviews and Meta-Analysis Protocols guidelines.

## Ethical Approval

The study protocol was approved by the Ethics Committee

of Kocaeli University Faculty of Medicine (approval number: GOKAEK-2023/11.27, dated: 16.06.2023).

## Statistical Analysis

Statistical analysis was performed using IBM SPSS Statistics 20.0 (IBM Corp., Armonk, NY, USA). The Kolmogorov-Smirnov test was used to assess the normality of data distribution. Continuous variables were presented as mean  $\pm$  standard deviation, while categorical variables were expressed as frequency (percentage). Since the assumption of normal distribution was not met, the Wilcoxon signed-rank test was used for comparisons between pretreatment and posttreatment values. Relationships between categorical variables were analyzed using the chi-squared test. A p-value of  $<0.05$  was considered statistically significant.

## Results

Over the past 5 years, *P. laurentii* was identified in culture samples from nine patients in our hospital. Of these, seven patients exhibited clinical findings indicative of infection, while two were classified as cases of colonization. A literature review identified 35 publications reporting a total of 40 cases of *P. laurentii* infection between 1998 and 2022 (Table 1). Among the infected patients, 66% were male, with a mean age of  $48.3 \pm 7.085$  years (range, 15-77 years). A summary of cases identified in our hospital and those reported in the literature is presented in Table 1.

## Case Presentations

### Case 1

A 42-year-old female patient with a history of asthma and hypothyroidism was admitted with fever and shortness of breath. She was started on ceftriaxone, clarithromycin, and treatment for an asthma attack. Chest computed tomography (CT) revealed several pulmonary nodules. Gram staining of a bronchoalveolar lavage (BAL) sample showed active inflammation based on Bartlett classification, with leukocytes and yeast cells present. *P. laurentii* was isolated in the BAL fungal culture. After 3 months of fluconazole treatment, follow-up CT showed a reduction in nodule size.

### Case 2

A 34-year-old female patient with a history of cryoglobulinemic vasculitis was admitted to the clinic with pneumonia, presenting with a 10 day history of cough and sputum production. She had been using prednisolone intermittently for 2 years. Chest CT showed pleural effusion adjacent to consolidation in the lower lobe of the right lung, along with a cavitary lesion. Additionally, tree-in-bud nodules and ground-glass opacities were observed in the lower lobe of the left lung. Fluconazole was added to her antibiotic regimen. Gram staining of sputum

samples showed numerous leukocytes but no microorganisms. *P. laurentii* was isolated in the sputum culture. After 6 months of fluconazole therapy, follow-up chest CT revealed the resolution of the ground-glass opacities, consolidation, cavity, and pleural effusion.

### Case 3

A 77-year-old male patient with no known comorbidities was hospitalized with Coronavirus Disease 2019 (COVID-19), confirmed by a Severe Acute Respiratory Syndrome Coronavirus 2 Polymerase Chain Reaction, tests. Chest CT showed diffuse bilateral ground-glass opacities, and his oxygen saturation was 75% on room air. He was started on antibiotics and pulse steroid therapy (250 mg for 3 days, followed by 40 mg of prednisolone). On the seventh and eighth days of hospitalization, he received two doses of tocilizumab. *P. laurentii* was isolated in a blood culture 8 days after pulse steroid therapy and 1 day after tocilizumab administration. The patient died on the same day.

### Case 4

A 43-year-old male patient with no known medical conditions underwent surgery for a duodenal perforation. He was started on meropenem and tigecycline. On the second day of hospitalization, *Enterococcus faecalis* and *P. laurentii* were isolated from the culture of the fluid collected from the surgical drain. Gram staining of the fluid showed numerous leukocytes and yeast cells. Fluconazole was added to his treatment regimen. The surgical drain was removed after 28 days of treatment, and the patient was discharged in full recovery.

### Case 5

A 67-year-old female patient with a history of diabetes mellitus, hypertension, and coronary artery disease was admitted to the Nephrology Department with postrenal acute kidney injury and required hemodialysis. She presented with dysuria, fatigue, and nausea. A pigtail catheter had been inserted approximately 1 year earlier. Urine culture from the patient, who had pyuria, revealed *P. laurentii* at a concentration of  $10^5$  colony-forming units (CFU). The pigtail catheter was replaced, and the patient completed a 7 day course of fluconazole before being discharged. Follow-up urine culture was negative, and pyuria was no longer present.

### Case 6

A 47-year-old male patient with hypertension was admitted to the intensive care unit with fever, shortness of breath, and cough. He developed acute kidney injury and required hemodialysis. A renal biopsy confirmed acute tubulointerstitial nephritis, for which he received 60 mg of prednisolone for 3 days. Two days later, *P. laurentii* was isolated in a sputum culture. However, as there was no evidence of active inflammation based on the Bartlett classification and no microorganisms detected in Gram

staining, the isolate was considered a case of colonization. The patient was discharged after completing antibiotic treatment.

### Case 7

A 15-year-old male patient with Duchenne muscular dystrophy underwent surgery in the Orthopedics Department for fractures of the right femur and humerus. On the sixth day of hospitalization, *P. laurentii* was isolated from a wound culture obtained from the surgical site. However, as leukocytes were absent in the sample, the isolate was considered a case of colonization rather than infection.

### Case 8

A 77-year-old male patient with a history of mitral valve replacement and a previous cerebrovascular stroke was admitted with a 45 day history of fever. Transesophageal echocardiography revealed an oscillating mass on the mitral valve. He was started on broad-spectrum antibiotics and was managed with a urinary catheter. One month later, after catheter removal, urine analysis showed 55 leukocytes, and urine culture yielded *P. laurentii* at a concentration of  $10^5$  CFU. The patient reported worsening fatigue and reduced oral intake, and his C-reactive protein level was elevated to 33 mg/l (normal upper limit: 5 mg/l). He was diagnosed with cystitis and started on fluconazole. Follow-up urine culture was negative. However, the patient died during surgical intervention for endocarditis.

### Case 9

A 33-year-old male patient with nasopharyngeal cancer was hospitalized with pneumonia. *P. laurentii* was isolated from a BAL sample. Gram staining of the BAL sample revealed leukocytes, yeast cells, and Gram-positive cocci. The patient was initially treated with amphotericin B for 5 days, followed by fluconazole. His treatment was completed in 14 days, leading to a full recovery.

## Systematic Review

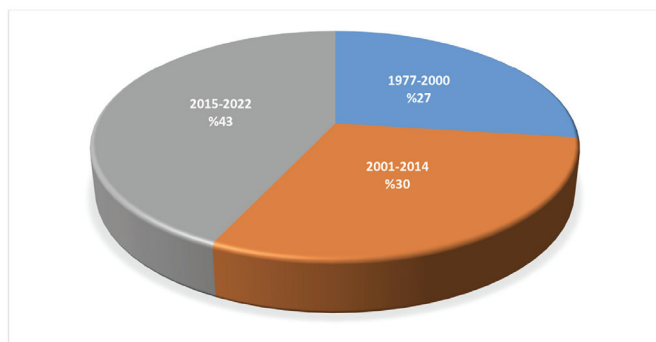
The first documented case of *P. laurentii*-associated infection was a cutaneous infection reported in 1977. Between 1977 and 2023, 43% of all identified cases were recorded. Among 40 reported cases of *P. laurentii* infection, 65.7% occurred in male patients, with a mean age of  $39.4 \pm 3.928$  years (age range, 0–88 years). The most frequently reported infection was fungemia, followed by meningitis and pneumonia. Less common infections included enteritis, skin ulcers, septic arthritis, endophthalmitis, lung abscesses, peritonitis, and mucositis. Notably, two cases of enteritis, one case of septic arthritis, and one case of endophthalmitis were newly reported in recent years (Figure 1). Broad-spectrum antibiotic use and the presence of invasive devices or catheters were frequently identified as risk factors in the literature<sup>[7,8]</sup>. Treatment primarily involved fluconazole and

amphotericin B. Among the 39 patients with available prognosis data, 33 (84.6%) recovered, while 5 (12.8%) died due to *P. laurentii* infection, and 1 (2.6%) succumbed to an underlying condition. Of the five patients who died from *P. laurentii* infection, two had fungemia, one had both meningitis and cutaneous infection, one had meningitis, and one had mucositis (Figure 2).

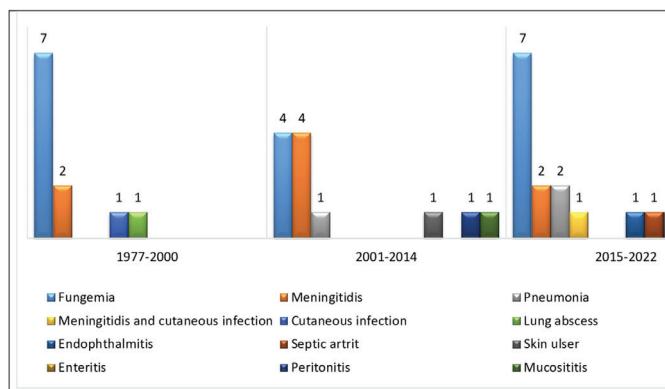
### Comparison of Our Cases with Published Data

The average age of our patients was 48.3 years, while the mean age of cases reported in the literature was 39.4 years. This difference was not statistically significant ( $p=0.302$ ). Male predominance was observed in both our study and the literature, with no significant difference between the two groups ( $p=0.641$ ).

In our study, pneumonia was the most frequently observed clinical manifestation, whereas fungemia was the most common presentation in the literature. Consistent with previous findings, broad-spectrum antibiotic use and the presence of invasive devices or catheters were identified as key risk factors for Cryptococcosis. A comparison of our hospital data with published cases is provided in Table 2.



**Figure 1.** *Cryptococcus laurentii* cases reported in the literature over the years



**Figure 2.** *Cryptococcus laurentii* infections reported in the literature over the years and the number of cases

## Discussion

This study presents seven cases of infection and two cases of colonization caused by *P. laurentii*, a rare human pathogen. To the best of our knowledge, this is the first report documenting *P. laurentii* cases in Türkiye. While immunocompromised individuals are generally considered at higher risk for *P. laurentii* infections, cases can also occur in immunocompetent patients.

Although *P. laurentii* has traditionally been regarded as a saprophyte and an uncommon human pathogen, reports of invasive infections have increased in recent years<sup>[9]</sup>. This rise may be linked to the growing number of immunocompromised individuals and the widespread use of immunosuppressive therapies<sup>[1]</sup>. Similarly, our findings align with the literature, as our cases also involved invasive infections.

Non-*neoformans* cryptococci are capable of infecting various organ systems. A study by Khawcharoenporn et al.<sup>[1]</sup> reported that bloodstream infections (39%) were the most common, followed by central nervous system infections (32%). In our study, one patient (14%) developed a bloodstream infection after receiving corticosteroids and cytokine blockers for COVID-19. Priscilla et al. also reported *P. laurentii* isolation from sputum culture under similar clinical conditions<sup>[10]</sup>. Additionally, a study of 30 COVID-19 patients found that corticosteroid and cytokine blocker therapy (e.g., tocilizumab) increased the risk of opportunistic cryptococcal infections<sup>[10]</sup>.

In our study, pulmonary Cryptococcosis was identified in three cases (42%). Cryptococcal lung disease can present in various forms, ranging from asymptomatic colonization to severe pneumonia with respiratory failure. Radiological findings may include pulmonary nodules, masses, segmental or lobar consolidation, reticulonodular infiltrates, mediastinal or hilar lymphadenopathy, and, less commonly, pleural effusion<sup>[9]</sup>. However, individuals with advanced HIV tend to exhibit more severe imaging abnormalities. Most case series have reported interstitial infiltrates as the predominant finding, while pleural effusions, cavitary lesions, adenopathy, and alveolar opacities are less frequently observed<sup>[11]</sup>. Additionally, endobronchial colonization has been documented in patients with chronic pulmonary disease, as seen in one case from our study<sup>[12]</sup>. The presence of yeast in urine cultures of asymptomatic individuals is typically regarded as colonization.

Current guidelines recommend that treatment for asymptomatic candiduria should focus on eliminating risk factors and should only be considered for patients at risk of disease progression<sup>[10]</sup>.

Invasive device use was identified as a risk factor in our study. Similarly, a review highlighted the presence of invasive devices as a significant risk factor for *P. laurentii* infection. One case report described *P. laurentii* as the causative agent of peritoneal

dialysis-associated peritonitis<sup>[13]</sup>. However, in our study, peritonitis developed in one patient, and the isolation of the pathogen after surgery may have been influenced by broad-spectrum antibiotic use or the presence of an invasive device.

**Table 1. Summary of our cases and systematically reviewed reported cases**

References	Country	Age/sex	Underlying condition	PAE/PSE	C-D/PN	Sample	Diagnosis	Manifestation	Treatment	Outcome
Our study	Türkiye	42/F	Asthma	No/inhale steroid	No/No	BAL	Pneumonia	Fever, dyspnea	F for 3 months	Cured
		34/F	Cryoglobulinemic vasculitis	No/Yes	No/No	Sputum	Pneumonia	Cough, sputum	F for 6 months	Cured
		77/M	COVID-19	Yes/Yes	No/No	Blood	Fungemia	NR	-	Died
		47/M	None	Yes/No	Yes/No	Peritoneal drainage catheter	Intraabdominal infection	NR	F for 1 month	Cured
		67/F	DM, hypertension, coronary artery disease	No/No	Yes/No	Urine	Urinary tract infection	NR	F for 7 days	Cured
		47/M	Hypertension	Yes/Yes	No/No	Sputum	Colonization	Fever, dyspnea, cough	-	Cured
		15/M	Duchenne muscular dystrophy	No/No	No/No	Skin	Colonization	Discharge in the wound	-	Cured
		77/M	Mitral valve replacement, cerebrovascular stroke	Yes/No	Yes/No	Urine	Urinary tract infection	NR	F for 2 weeks	Cured
		33/M	Nasopharyngeal cancer	Yes/No	No/No	BAL	Pneumonia	Dyspnea	Amp B for 5 days followed by F for 9 days	Cured
Deepa et al. <sup>[14]</sup>	India	50/M	DM, COVID-19	Yes/Yes	No/No	Vitreous	Endophthalmitis	6 weeks of progressive blurred vision	Topical V for 9 months, oral F for 1 month	Cured
Al-Otaibi et al. <sup>[7]</sup>	Kuwait	Newborn	Very low birth weight	Yes/No	Yes/No	Blood	Fungemia	Abdominal distension and weight loss	Amp B for 14 days	Cured
Huang et al. <sup>[6]</sup>	China	29/M	History of plant-related scratches	Yes/Yes	No/No	Joint fluid	Septic arthritis	Knee pain and limited activity	A month of treatment with topical V and knee irrigation with Amp B. The treatment continued with F for nearly 7 months	Cured
Castro-Lainez et al. <sup>[15]</sup>	USA	59/M	DM	Yes/NR	No/No	CSF	Meningitis	Headache, blurred vision, disequilibrium, and photophobia	Amp B and F for 6 weeks	Cured
Londero et al. <sup>[8]</sup>	Brazil	68/F	DM, breast cancer with radical mastectomy	Yes/No	Yes/No	Catheter and peripheral blood	Fungemia	Fever and abdominal pain	Catheter removed and Amp B and F for 2 weeks	Cured
Zhang et al. <sup>[16]</sup>	China	50/M	HIV	No/NR	NR/No	Skin and CSF	Meningitis and cutaneous infection	Skin lesions	Amp B and F	Died
		64/F	HIV	Yes/NR	NR/No	BAL	Pneumonia	Mild fever, productive cough, dyspnea	F	Cured
Gupta et al. <sup>[17]</sup>	India	6 days/M	Premature	Yes/No	Yes/No	Blood	Fungemia	Worsening of the clinical condition	IV Amp B for 8 days followed by F for 24 days	Cured



**Table 1. Continued**

References	Country	Age/sex	Underlying condition	PAE/PSE	C-D/PN	Sample	Diagnosis	Manifestation	Treatment	Outcome
Ding et al. <sup>[18]</sup>	Malaysia	35/F	Hodgkin's lymphoma	Yes/No	No/No	Blood	Fungemia	Supraclavicular mass, fever	F for 2 weeks	Cured
Park et al. <sup>[19]</sup>	Korea	47/F	Refractory AML after allogenic HSCT	Yes/NR	NR/Yes	Blood and skin	Fungemia	Fever and erythematous papules	Amp B for 3 weeks	Cured
Martinez et al. <sup>[20]</sup>	Mexico	65/M	Cutaneous leishmaniasis	No/No	No/No	Skin biopsy	Skin ulcer	Ulcer	Itraconazole	Cured
Bhat et al. <sup>[21]</sup>	India	26/F	Hodgkin's lymphoma autologous HSCT	No/NR	NR/No	Stool	Enteritis	Diarrhea	V for 4 weeks	Cured
Calista et al. <sup>[22]</sup>	Italy	74/M	Hepatitis B, colorectal cancer on chemotherapy	Yes/NR	NR/Yes	Stool	Enteritis	Diarrhea	Amp B for 10 days	Cured
Cheng et al. <sup>[23]</sup>	Taiwan	88/F	Right breast cancer (postmastectomy), diffuse large B-cell lymphoma	Yes/Yes	NR/Yes	Blood	Fungemia	Fever	Amp B and flucytosine for 2 weeks	Cured
Conti et al. <sup>[24]</sup>	Italy	47/F	SLE and Sjogren syndrome treated with cyclosporine A and corticosteroids	Yes/Yes	NR/No	BAL	Pneumonia	Cough, fever	Initially Amp B, switched to F for 8 months due to toxicity	Cured
Mittal et al. <sup>[25]</sup>	India	30/F	Recent C-section due to fetal distress	Yes/NR	NR/No	CSF	Meningitidis	Postpartum headache and drowsiness	Amp B	Died
Neves et al. <sup>[26]</sup>	Brazil	42/M	Cervical cancer treated with chemotherapy and radiotherapy	Yes/NR	NR/No	Blood	Fungemia	Fever and abdominal pain	F for 22 weeks	Cured
Asano et al. <sup>[13]</sup>	Japan	32/M	IgA neuropathy in PD	No/No	Yes (PD)/ No	Peritoneal fluid	Peritonitis	Fever	Removal of the PD catheter and V for 3 months	Cured
Banerjee et al. <sup>[27]</sup>	India	76/M	Hypertension, coronary artery disease, and previous hemorrhagic stroke	Yes/No	Cardiac defibrillator implantation 2 weeks before fungemia/ No	Blood	Fungemia	Fever, shortness of breath, heart failure	Amp B for 2 weeks followed by F for 2 weeks	Cured
Molina-Leyva et al. <sup>[28]</sup>	Spain	8/F	None	No/No	No/No	Skin biopsy	Skin ulcer	Skin lesion in the right forearm	F for 2 weeks	Cured
Rodríguez et al. <sup>[29]</sup>	Colombia	3 months/M	Premature baby with down syndrome	Yes/No	Yes/No	Blood	Fungemia	Respiratory failure	Amp B	Died
Furman-Kuklinska et al. <sup>[30]</sup>	Polonia	39/M	Type I membranoproliferative glomerulonephritis,	No/Yes	No/No	Blood	Fungemia	Fever	Itraconazole for 4 weeks due to persistent fungemia	Cured
Khawcharoenporn et al. <sup>[31]</sup>	Thailand	35/M	HIV	NR/NR	NR/NR	Blood and CSF	Meningitidis	Fever, headache	Amp B for 14 days followed by F for 3 months	Cured
Manfredi et al. <sup>[32]</sup>	Italy	34/M	HIV, IV drug user, previous <i>C. neoformans</i> meningitis	No/No	No/No	CSF	Meningitidis	Fever, headache	F for 46 days	Cured
Shankar et al. <sup>[33]</sup>	India	35/F	HIV, DM	Yes/No	No/No	Pleural fluid	Pneumonia	Fever, night sweats, pleuritic chest pain, and dyspnea	F for 5 weeks	Cured

**Table 1. Continued**

References	Country	Age/sex	Underlying condition	PAE/PSE	C-D/PN	Sample	Diagnosis	Manifestation	Treatment	Outcome
Simon et al. <sup>[34]</sup>	Hungary	9/M	X- linked hyperimmunoglobulin M syndrome	Yes/No	No/Yes	CSF	Meningitidis	Headache, nausea, and somnolence	F for 9 months with tittering of dosage	Cured
Vlchкова-Lashkoska et al. <sup>[35]</sup>	Slovakia	51/M	Alcoholism	No/No	No/No	Skin and CSF	Meningitidis	Skin lesion on the back	NR	NR
Averbuch et al. <sup>[36]</sup>	Israel	16/M	Metastatic ganglioneuroblastoma	Yes/No	Yes/No	Blood	Fungemia	Fever	Amp B for 3 weeks	Cured
Bauters et al. <sup>[36]</sup>	Belgium	45/M	Erythroleukemia	Yes/NR	NR/Yes	Oropharynx	Mucositis	Fever	Amp B for 18 days	Died
Kunova and Krcmery et al. <sup>[38]</sup>	Slovakia	NR	Neutropenia	Yes/NR	Yes/Yes	Blood	Fungemia	Fever	F for 10 days	Cured
		NR	Neutropenia	Yes/NR	Yes/Yes	Blood	Fungemia	Fever	Amp B for 14 days	Cured
		NR	Neutropenia	Yes/NR	No/Yes	Blood	Fungemia	Fever	NR	Died
Kordosis et al. <sup>[39]</sup>	Greece	34/M	HIV and Kaposi's sarcoma	No/No	No/No	CSF	Meningitidis	Fever, headache, and diplopia	Amp B and flucytosine for 2 weeks followed by F as a maintenance therapy	Cured
Kunova and Krcmery et al. <sup>[38]</sup>	Slovakia	NR/M	Solid tumor	Yes/No	Yes/Yes	Blood	Fungemia	NR	F	Cured
		NR/M	nonHodgkin's lymphoma	Yes/Yes	Yes/Yes	Blood	Fungemia	NR	Amp B	Died due to underlying disease
Johnson et al. <sup>[40]</sup>	USA	27 days/M	Premature	Yes/No	Yes/No	Blood	Fungemia	NR	Amp B and flucytosine	Cured
		27/F	IV drug use, bacterial endocarditis, and bipolar disorder	Yes/No	NR/No	Blood	Fungemia	Fever and painful cutaneous nodules	F	Cured
Lynch et al. <sup>[41]</sup>	USA	55/F	Adenocarcinoma, dermatomyositis	No/Yes	NR/No	NR	Lung abscess	Asymptomatic right upper lobe cavitary lesion	Amp B	Cured
Kamalam et al. <sup>[42]</sup>	India	40/M	Mycobacterial skin infection	NR/NR	NR/NR	Skin	Cutaneous infection	Cutaneous granulomas in the leg and foot	Amp B	Cured

PAE: Prior antibiotic exposure, PSE: Prior steroid exposure, C-D: Catheter device, PN: Prior neutropenia, BAL: Bronchoalveolar lavage, DM: Diabetes mellitus, Amp B: Amphotericin B, F: Fluconazole, V: Voriconazole, IV: Intravenous, PD: Peritoneal dialysis, HSCT: Hematopoietic stem cell transplantation, SLE: Systemic lupus erythematosus, CSF: Cerebrospinal fluid, NR: Not reported, HIV: Human immunodeficiency virus, AML: Acute myeloid leukemia

**Table 2. Comparison of patient data with literature case reports**

Characteristics	Case series (n=9)	Literature cases (n=40)	p-value
Age, mean years	48.3 + 7.085 (15–77)	39.4+3.928 (0–88)	0.302
Male, sex	6 (66%)	23 (65.7%)	0.641
<b>Risk factors, n (%)</b>			
• Invasive devices or catheter	2 (22%)	12 (30%)	
• Prior steroid exposure	3 (33%)	7 (17.5%)	
• Anti-interleukin	1 (11%)	1 (2.5%)	
• Broad-spectrum antibiotic	2 (22%)	27 (67%)	
• Solid tumor	1 (11%)	7 (17%)	
• HIV	0	6 (15%)	
• Lymphoma or leukemia	0	4 (10%)	
• DM	1 (11%)	4 (10%)	
<b>Clinical manifestations, n (%)</b>			
• Blood stream infection	1 (11%)	18 (45%)	
• Pulmonary infection	4 (44%)	3 (7%)	
• Peritonitis	1 (11%)	1 (2.5%)	
• Urinary tract infection	2 (22%)	–	
• Meningitis		8 (20%)	
• Meningitis and cutaneous infection		1 (2.5%)	
• Enteritis		2 (5%)	
• Skin ulcer		2 (5%)	
• Cutaneous infection		1 (2.5%)	
• Endophthalmitis		1 (2.5%)	
• Lung abscess		1 (2.5%)	
• Septic arthritis		1 (2.5%)	
• Mucositis	1 (11%)	1 (2.5%)	
<b>Treatment, n (%)</b>			
• Fluconazole	6 (66%)	20 (50%)	
• Amphotericin B	1 (11%)	22 (55%)	
• No treatment	2 (22%)	–	
• Voriconazole	–	4 (10%)	
• Flucytosine	–	3 (7%)	
• Itraconazole	–	2 (5%)	
<b>Outcome, n (%)</b>			
• Cured	8 (88%)	35 (87%)	
• Died	1 (11%)	5 (13%)	

DM: Diabetes mellitus, HIV: Human immunodeficiency virus

## Conclusion

In summary, an evaluation of these nine cases indicates that *P. laurentii*, though considered a rare pathogen, can cause infections in multiple organ systems. Successful treatment can be achieved with appropriate antifungal therapy initiated based on thorough clinical evaluation and culture results. However, delays in treating systemic infections may result in fatal outcomes. Therefore, it is important to recognize that this rare pathogen can act as an infectious agent, particularly in patients receiving broad-spectrum antibiotics or steroid therapy.

## Ethics

**Ethics Committee Approval:** The study protocol was approved by the Ethics Committee of Kocaeli University Faculty of Medicine (approval number: GOKAEK-2023/11.27, dated: 16.06.2023).

**Informed Consent:** Retrospective study.

## Footnotes

## Authorship Contributions

Surgical and Medical Practices: M.T.D., Design: S.A., Data Collection or Processing: M.T.D., Analysis or Interpretation: S.A., Literature Search: S.A., Writing: M.T.D.

**Conflict of Interest:** No conflict of interest was declared by the authors.

**Financial Disclosure:** The authors declared that this study received no financial support.

## References

- Khawcharoenporn T, Apisarnthanarak A, Mundy LM. Non-neoformans cryptococcal infections: a systematic review. *Infection*. 2007;35:51–8.
- Zonios DI, Falloon J, Huang C-Y, Chait D, Bennett JE. Cryptococcosis and idiopathic CD4 lymphocytopenia. *Medicine (Baltimore)*. 2007;86:78–92.
- Morales-López SE, Garcia-Effron G. Infections due to rare *Cryptococcus* species. A literature review. *J Fungi (Basel, Switz.)* 2021;7:279.
- Setianingrum F, Rautemaa-Richardson R, Denning DW. Pulmonary cryptococcosis: A review of pathobiology and clinical aspects. *Med Mycol*. 2019;57:133–50.
- Ej C, Za Y, Rr R. *Cryptococcus* species other than *Cryptococcus neoformans* and *Cryptococcus gattii*: Are they clinically significant? *Open Forum Infect Dis*. 2020;7.
- Huang H, Pan J, Yang W, Lin J, Han Y, Lan K, Zeng L, Liang G, Liu J. First case report of *Cryptococcus laurentii* knee infection in a previously healthy patient. *BMC Infect Dis*. 2020;20:681.
- Al-Otaibi H, Asadzadeh M, Ahmad S, Al-Sweih N, Joseph L. *Papillotrema laurentii* fungemia in a premature, very low-birth-weight neonate in Kuwait successfully treated with liposomal amphotericin B. *J Mycol Med*. 2021;31:101123.
- Londero MR, Zanolto CD, Corso LL, Michelin L, Soldera J. Catheter-related infection due to *Papillotrema laurentii* in an oncologic patient: Case report and systematic review. *Braz J Infect Dis*. 2019;23:451–61.



9. Chang WC, Tzao C, Hsu HH, Lee SC, Huang KL, Tung HJ, Chen CY. Pulmonary cryptococcosis: comparison of clinical and radiographic characteristics in immunocompetent and immunocompromised patients. *Chest*. 2006;129:333-40.
10. Luciano PD. Non-neoformans pulmonary cryptococcosis due to *Cryptococcus laurentii* in a 30 positive SARS-COV-2 patient. *Case Reports in Clinical Practice*. 2022;7:5.
11. Kelly S, Marriott D. Miliary pulmonary cryptococcosis. *Med Mycol Case Rep*. 2014;6:22-4.
12. Neuville S, Dromer F, Morin O, Dupont B, Ronin O, Lortholary O; French Cryptococcosis Study Group. Primary cutaneous cryptococcosis: a distinct clinical entity. *Clin Infect Dis*. 2003;36:337-47.
13. Asano M, Mizutani M, Nagahara Y, Ueda H. Successful treatment of *Cryptococcus laurentii* peritonitis in a patient on peritoneal dialysis. *Intern Med (Tokyo, Jpn.)*. 2015;54:941-4.
14. Deepa MJ, Megharaj C, Patil S, Rani PK. *Cryptococcus laurentii* endogenous endophthalmitis post COVID-19 infection. *BMJ Case Rep*. 2022;15:e246637.
15. Castro-Lainez MT, Deliz-Aguirre R, Antunez D, Cruz-Codina M, Cahuayme-Zuniga L, Vitale K, Sierra-Hoffman M, Midturi JK. *Cryptococcus laurentii* meningitis in a non-HIV patient. *IDCases*. 2019;18:e00612.
16. Zhang Y, Cooper B, Gui X, Sherer R, Cao Q. Clinical diversity of invasive cryptococcosis in AIDS patients from central China: report of two cases with review of literature. *BMC Infect Dis*. 2019;19:1003.
17. Gupta M, Mishra AK, Singh SK. *Cryptococcus laurentii* fungemia in a low birth weight preterm neonate: India. *J Infect Public Health*. 2018;11:896-7.
18. Ding C-H, Kamarudin N, Lim YM, Cheong H. Non-neoformans cryptococemia in a patient with Hodgkin's lymphoma. *Asian J Pharm Clin Res*. 2018;11:7.
19. Park SS, Lee H, Park WS, Hwang SH, Choi SI, Choi MH, Lee SW, Ko EJ, Choi YJ, Eom HS. A case of disseminated infection with skin manifestation due to non-neoformans and non-*gattii* *Cryptococcus* in a patient with refractory acute myeloid leukemia. *Infect Chemother*. 2017;49.
20. Martínez E, Torres-Guerrero E, Cortés E, Tejada D, Arenas R. *Cryptococcus laurentii* infection in a patient with cutaneous leishmaniasis. *Int J Dermatol*. 2017;56:e56-7.
21. Bhat V, Vira H, Khattri N, Toshniwal M. *Cryptococcus laurentii* diarrhea post hematopoietic stem cell transplant. *Transpl Infect Dis*. 2017;19.
22. Calista F, Tomei F, Assalone P, D'Amico G, Di S. *Cryptococcus laurentii* diarrhea in a neoplastic patient. *Case Rep Oncol Med*. 2015;2015:216458.
23. Cheng M-W, Wu AYJ, Liu C-P, Lim K-H, Weng S-L, Tseng H-K. Cryptococemia in an elderly woman with retroperitoneal diffuse large B-cell lymphoma after rituximab-containing chemotherapy. *Int J Gerontol*. 2016;10:112-6.
24. Conti F, Spinelli FR, Colafrancesco S, Truglia S, Ceccarelli F, Fattapposta F, Sorice M, Capozzi A, Ferretti G, Priori R, Martinelli F, Pirone C, Alessandri C, Valesini G. Acute longitudinal myelitis following *Cryptococcus laurentii* pneumonia in a patient with systemic lupus erythematosus. *Lupus*. 2015;24:94-7.
25. Mittal N, Vatsa S, Minz A. Fatal meningitis by *Cryptococcus laurentii* in a post-partum woman: A manifestation of immune reconstitution inflammatory syndrome. *Indian J Med Microbiol*. 2015;33:590-3.
26. Neves RP, Lima Neto RG, Leite MC, Silva VK, Santos Fde A, Macêdo DP. *Cryptococcus laurentii* fungaemia in a cervical cancer patient. *Braz J Infect Dis*. 2015;19:660-3.
27. Banerjee P, Haider M, Trehan V, Mishra B, Thakur A, Dogra V, Loomba P. *Cryptococcus laurentii* fungemia. *Indian J Med Microbiol*. 2013;31:75-7.
28. Molina-Leyva A, Ruiz-Carrascosa JC, Leyva-Garcia A, Husein-Elahmed H. Cutaneous *Cryptococcus laurentii* infection in an immunocompetent child. *Int J Infect Dis*. 2013;17:e1232-1233.
29. Rodríguez DA, Pinilla AP. Infección asociada a catéter central por *Cryptococcus laurentii* en niño críticamente enfermo: a propósito de un caso y revisión del tema. *Infectio*. 2012;16:72-4.
30. Furman-Kuklińska K, Naumnik B, Myśliwiec M. Fungaemia due to *Cryptococcus laurentii* as a complication of immunosuppressive therapy-a case report. *Adv Med Sci*. 2009;54:116-9.
31. Khawcharoenporn T, Apisarnthanarak A, Kiratisin P, Mundy L M, Bailey TC. Evaluation of *Cryptococcus laurentii* meningitis in a patient with HIV infection: a case report and review of the literature. *Hawaii Med J*. 2006;65:260-3.
32. Manfredi R, Fulgaro C, Sabbatani S, Legnani G, Fasulo G. Emergence of amphotericin B-resistant *Cryptococcus laurentii* meningoencephalitis shortly after treatment for *Cryptococcus neoformans* meningitis in a patient with AIDS. *AIDS Patient Care STDs*. 2006;20:227-32.
33. Shankar EM, Kumarasamy N, Bella D, Sivarajan S, Pradeep M, Manogaran. Pneumonia and pleural effusion due to *Cryptococcus laurentii* in a clinically proven case of AIDS. *Can Respir J*. 2006;13:275-8.
34. Simon G, Simon G, Erdős M, Maródi L. Invasive *Cryptococcus laurentii* disease in a nine-year-old boy with X-linked hyper IgM syndrome. *Pediatr Infect Dis J*. 2005;24:53-5.
35. Vlachova-Lashkoska M, Kamberova S, Starova A, Goleva-Mishevskia L, Tsatsa-Biljanovska N, Janevska V, Petrovska M. Cutaneous *Cryptococcus laurentii* infection in a human immunodeficiency virus-negative subject. *J Eur Acad Dermatol Venereol JEADV*. 2004;18:99-100.
36. Averbuch D, Boekhout T, Falk R, Engelhard D, Shapiro M, Block C, Polacheck I. Fungemia in a cancer patient caused by fluconazole-resistant *Cryptococcus laurentii*. *Med Mycol*. 2002;40:455-60.
37. Bauters TGM, Swinne D, Boekhout T, Noens L, Nelis HJ. Repeated isolation of *Cryptococcus laurentii* from the oropharynx of an immunocompromized patient. *Mycopathologia*. 2002;153:133-5.
38. Kunova A, Krcmery V. Fungaemia due to thermophilic cryptococci: 3 cases of *Cryptococcus laurentii* bloodstream infections in cancer patients receiving antifungals. *Scand J Infect Dis*. 1999;31:328.
39. Kordossis T, Avlami A, Velegraki A, Stefanou I, Georgakopoulos G, Papalambrou C, Legakis NJ. First report of *Cryptococcus laurentii* meningitis and a fatal case of *Cryptococcus albidus* cryptococcaemia in AIDS patients. *Med Mycol*. 1998;36:335-9.
40. Johnson LB, Bradley SF, Kauffman CA. Fungaemia due to *Cryptococcus laurentii* and a review of non-neoformans cryptococcaemia. *Mycoses*. 1998;41:277-80.
41. Lynch JP, Schaberg DR, Kissner DG, Kauffman CA. *Cryptococcus laurentii* lung abscess. *Am Rev Respir Dis*. 1981;123(1):135-8.
42. Kamalam A, Yesudian P, Thambiah AS. Cutaneous infection by *Cryptococcus laurentii*. *Br J Dermatol*. 1977;97(2):221-3.