

DOI: 10.4274/mjima.galenos.2025.24327.5  
Mediterr J Infect Microb Antimicrob 2025;14:24327.5  
Erişim: <http://dx.doi.org/10.4274/mjima.galenos.2025.24327.5>

# A Case of Lumbar Spondylodiscitis and Psoas Abscess Caused by *Candida albicans*

## *Candida albicans*'a Bağlı Lomber Spondilodiskit ve Psoas Apsesi Olgusu

© Hasibullah YAQOOBİ<sup>1\*</sup>, © Yusuf Ziya DEMİROĞLU<sup>1</sup>, © Hayriye ALTUNAY<sup>1</sup>, © Halil İbrahim SÜNER<sup>2</sup>, © Tunzala ASGAROVA<sup>3</sup>

<sup>1</sup>Başkent University, Adana Dr. Turgut Noyan Application and Research Center, Yüreğir Capital Hospital, Department of Infectious Diseases and Clinical Microbiology, Adana, Türkiye

<sup>2</sup>Başkent University Adana Dr. Turgut Noyan Application and Research Center, Yüreğir Capital Hospital, Department of Brain and Nerve Surgery, Adana, Türkiye

<sup>3</sup>Başkent University Adana Dr. Turgut Noyan Application and Research Center, Yüreğir Capital Hospital, Department of Medical Microbiology, Adana, Türkiye

### Abstract

Bone and joint infections due to candidiasis are rare. The simultaneous occurrence of lumbar spondylodiscitis and psoas abscess is rare. Furthermore, although *Candida albicans* remains the most common causative agent, recent reports have indicated a rise in non-*albicans* *Candida* species. In this report, we have presented a case of lumbar spondylodiscitis and psoas abscess that was associated with *C. albicans*-induced candidemia.

**Keywords:** *Candida albicans*, spondylodiscitis, psoas abscesses

### Öz

Kandidozlara bağlı kemik ve eklem enfeksiyonları nadirdir. *Candida* kökenlerine bağlı lomber spondilodiskit ve psoas apsesi birlikteliği ise oldukça nadir görülen bir klinik tablodur. Etken olarak en sık *Candida albicans* görülmekle birlikte son yıllarda *albicans* dışı *Candida* sıklığının da arttığı bildirilmektedir. Burada *C. albicans* kandidemisine bağlı bir lomber spondilodiskit ve psoas apsesi olgusu sunulmuştur.

**Anahtar Kelimeler:** *Candida albicans*, spondilodiskit, psoas absesi

### Introduction

Spondylodiscitis and psoas abscess that are caused by *Candida* species are rare clinical conditions. Although the infection often occurs as a result of hematogenous spread, it can also develop via direct extension and contiguity. In adults, skeletal involvement, particularly vertebral involvement, is common. However, other bone structures can also be affected. *Candida albicans* is the most common pathogen. However, in recent years, the incidence of spondylodiscitis caused by non-*albicans* *Candida* species

has increased. Because the clinical and radiological findings of spondylodiscitis and psoas abscess caused by *Candida* species are non-specific, the disease can be frequently overlooked<sup>[1]</sup>. Herein, we have presented a case of lumbar spondylodiscitis and psoas abscess that was associated with candidemia due to *C. albicans*.

### Case Report

A 33-year-old female presented to our clinic with complaints of lower back pain. Her medical history included hemophilia

**Cite this article as:** Yaqoobi H, Demiroğlu YZ, Altunay H, Süner Hİ, Asgarova T. A Case of Lumbar Spondylodiscitis and Psoas Abscess Caused by *Candida albicans*. Mediterr J Infect Microb Antimicrob 2025;14:24327.5.



Address for Correspondence/Yazışma Adresi: Hasibullah Yaqoobi, MD. Başkent University, Adana Dr. Turgut Noyan Application and Research Center, Yüreğir Capital Hospital, Department of Infectious Diseases and Clinical Microbiology, Adana, Türkiye  
E-mail: [h\\_yaqoobi@hotmail.com](mailto:h_yaqoobi@hotmail.com) ORCID ID: [orcid.org/0000-0002-8865-7212](https://orcid.org/0000-0002-8865-7212)  
Received/Geliş Tarihi: 18.10.2024 Accepted/Kabul Tarihi: 23.01.2025

Epub: 27.01.2025  
Published: 13.03.2025



©Copyright 2025 by the Infectious Diseases and Clinical Microbiology Specialty Society of Turkey Mediterranean Journal of Infection, Microbes and Antimicrobials published by Galenos Yayınevi. Licensed under a Creative Commons Attribution-NonCommercial-NoDerivatives 4.0 International License (CC BY-NC-ND 4.0).

A and recurrent vulvovaginitis. Eight months prior to her visit, her pregnancy was terminated at 3 months of gestation due to placenta previa. Furthermore, a hysterectomy with salpingoophorectomy was performed. Five days postoperatively, she developed deep vein thrombosis of the right lower extremity and pulmonary embolism. During her hospital stay, a nephrostomy catheter was placed for a right-sided hydronephrosis. Following the development of pyelonephritis, *C. albicans* was detected in both blood cultures and urine cultures obtained from the nephrostomy. After 20 days of treatment, she was discharged. Subsequently, she developed vision loss in her right eye and was diagnosed with *Candida* endophthalmitis. She underwent a surgical intervention, and voriconazole treatment was initiated. However, the patient was noncompliant with the treatment regimen. Four months after the hysterectomy and nephrostomy, she developed lower back pain. The patient reported that despite physical therapy, the pain persisted. Thus, she was admitted to our department for further treatment.

A physical examination revealed a good general condition and stable vital signs. Furthermore, her lower back movements were painful. The gynecological examination revealed vulvovaginitis, which was treated. No active inflammation was detected during the eye examination. Laboratory tests revealed a C-reactive protein level of 36 mg/dL and an erythrocyte sedimentation rate of 55 mm/h. Other laboratory findings were within the normal ranges.

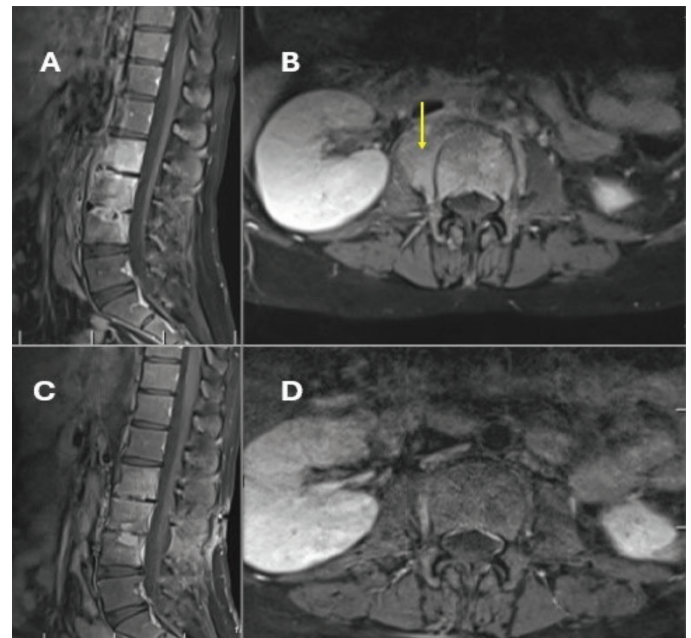
The patient was hospitalized. No growth was detected in the blood and urine cultures. The Brucella standard tube agglutination test yielded a negative result. Transthoracic echocardiography and orbital magnetic resonance imaging (MRI) did not reveal any abnormalities. The lumbar MRI revealed spondylodiscitis at the L2, L3, and L4 levels, with intense contrast enhancement in the psoas muscle, indicating an abscess (Figure 1). A percutaneous transpedicular biopsy of the lumbar vertebrae and disks was performed by a neurosurgeon. Bacterial and tuberculosis (TB) cultures of the tissue samples did not yield any growth, and the TB polymerase chain reaction (PCR) test yielded a negative result. Pathological examination of the specimen showed no evidence of malignancy. *C. albicans*, susceptible to treatment, was isolated from the fungal culture of the tissue sample. The patient was discharged with oral fluconazole (400 mg once daily) for 6–12 months. From the 15<sup>th</sup> day of treatment, significant clinical and laboratory improvement was observed. By the 8<sup>th</sup> month of follow-up, the clinical, laboratory, and radiological test results demonstrated a good response to fluconazole. The follow-up MRI at the 6<sup>th</sup> month revealed significant regression of the psoas muscle abscess and spondylodiscitis findings (Figure 1). Fluconazole was discontinued at the 9<sup>th</sup> month follow-up.

## Discussion

In Türkiye, some studies have focused on osteoarticular infections and psoas abscesses. However, no study or case report has specifically documented the co-existence of spondylodiscitis and psoas abscess caused solely by *Candida* species<sup>[1]</sup>. Therefore, the epidemiology of such cases in Türkiye is not well understood. Thus, our case findings contribute to the limited national literature.

In a PRISMA-based review, the PubMed, Web of Science, Embase, Scopus, and OVID Medline databases were searched from their inceptions to November 30, 2022, using terms related to *Candida spondylodiscitis*. The search yielded 625 studies. Of these, 72 studies met the inclusion criteria and were included in the review. The number of patients with *Candida* spondylodiscitis was 89. Furthermore, *C. albicans* accounted for 62% of the cases, while non-*albicans Candida* species (e.g., *Candida tropicalis*, *Candida glabrata*, *Candida parapsilosis*, and *Candida krusei*) accounted for 32% of the cases.

In our patient, although there was no known immunosuppression other than the pregnancy, the clinical condition developed following a history of recurrent vulvovaginitis, placenta previa, and *C. albicans*-associated pyelonephritis, which had led to candidemia. Additionally, there are studies on psoas abscesses caused by *Candida* species (e.g., *C. albicans*, *C. glabrata*, and



**Figure 1.** (A, B) Pre-treatment, contrast-enhanced, T1-weighted, sagittal and axial MRI showing spondylitis at the L2, L3, and L4 vertebrae and an abscess in the right psoas muscle (yellow arrow). (C, D) Post-treatment MRI showing regression of spondylitis and the abscess

MRI: Magnetic resonance imaging

*C tropicalis*)<sup>[3-5]</sup>. However, our patient appears to be the first to present with both a psoas abscess and lumbar spondylodiscitis. The most significant clinical finding in *Candida*-associated spondylodiscitis and psoas abscess is lower back pain, in addition to restricted movements of the lower back and extremities<sup>[1]</sup>. Our patient presented with lower back pain.

Laboratory findings such as C-reactive protein level, sedimentation rate, beta-D-glucan level, procalcitonin level, and leukocyte count, as well as imaging modalities such as computed tomography and MRI, are not sufficient for making a definitive diagnosis<sup>[1,2]</sup>. Ultrasound-guided biopsy, computed tomography-guided biopsy, and tissue sampling via open surgery are the current standard methods for identifying the causative pathogen and determining the differential diagnoses<sup>[6,7]</sup>. In our patient, an open surgical biopsy was performed as a minimally invasive procedure for diagnostic purposes. Subjecting the biopsy specimen to bacterial and fungal cultures, TB culture, PCR, and pathological examination is essential for establishing a definitive diagnosis. In our patient, *C. albicans* was isolated from the fungal culture. For the treatment of *Candida*-associated spondylodiscitis and psoas abscess, fluconazole at a dose of 6 mg/kg/day for 6–12 months has been strongly recommended as an empirical antifungal therapy. A regimen consisting of 2 weeks of echinocandin (e.g., caspofungin, micafungin, and anidulafungin) or liposomal amphotericin B at 3–5 mg/kg/day, followed by fluconazole at 6 mg/kg/day for 6–12 months, has also been suggested. Another important aspect of treatment is surgery. Surgical intervention should be considered in appropriate candidates on the basis of patient-specific findings<sup>[8]</sup>.

## Conclusion

In conclusion, *Candida* species should be considered as potential pathogens in patients presenting with spondylodiscitis and a psoas abscess.

## Ethics

**Informed Consent:** Informed consent was obtained.

## Footnotes

### Authorship Contributions

Surgical and Medical Practices: H.Y., Y.Z.D., H.A., H.İ.S., Concept: H.Y., Y.Z.D., T.A., Design: H.Y., Y.Z.D., H.A., Data Collection or Processing: H.Y., Y.Z.D., H.A., T.A., Analysis or Interpretation: H.Y., Y.Z.D., H.A., T.A., Literature Search: H.Y., Y.Z.D., Writing: H.Y., Y.Z.D.

**Conflict of Interest:** No conflict of interest was declared by the authors.

**Financial Disclosure:** The authors declared that this study received no financial support.

## References

1. Aksoy F, Aydın N, Çakır E, Koçak M, Oğuz Ş, Özkaya E, Tosun İ, Yılmaz G, Köksal İ. Osteoarticular *Candida* infection: report of three cases and literature review of 44 patients. *Mediterr J Infect Microb Antimicrob*. 2019;8:30.
2. Adelhoef SJ, Gonzalez MR, Bedi A, Kienzle A, Bäcker HC, Andronic O, Karczewski D. *Candida spondylodiscitis*: a systematic review and meta-analysis of seventy two studies. *Int Orthop*. 2024;48:5-20.
3. Fukuhara S, Nishimura K, Yoshimura K, Okuyama A, Yamato M, Kawamori D, Matsuhiya M. A case of psoas abscess caused by *Candida albicans*. *Hinyokika Kyo*. 2003;49:141-3.
4. Nagarakanti S, Bishburg E. Psoas abscess caused by *Candida glabrata*: a case report. *Cureus*. 2020;12:e10614.
5. Miloudi M, Belabbes S, Sbaai M, Kamouni YE, Arsalane L, Zouhair S. Abcès de psoas à *Candida tropicalis*: à propos d'un cas [Psoas abscess due to *Candida tropicalis*: a case report]. *Ann Biol Clin (Paris)*. 2018;76:571-3.
6. Matsumoto T, Yamagami T, Morishita H, Iida S, Asai S, Masui K, Yamazoe S, Sato O, Nishimura T. CT-guided percutaneous drainage within intervertebral space for pyogenic spondylodiscitis with psoas abscess. *Acta Radiol*. 2012;53:76-80.
7. Dave BR, Kurupati RB, Shah D, Degulamadi D, Borgohain N, Krishnan A. Outcome of percutaneous continuous drainage of psoas abscess: a clinically guided technique. *Indian J Orthop*. 2014;48:67-73.
8. Pappas PG, Kauffman CA, Andes DR, Clancy CJ, Marr KA, Ostrosky-Zeichner L, Reboli AC, Schuster MG, Vazquez JA, Walsh TJ, Zaoutis TE, Sobel JD. Clinical practice guideline for the management of *Candidiasis*: 2016 update by the Infectious Diseases Society of America. *Clin Infect Dis*. 2016;62:1-50.